

See discussions, stats, and author profiles for this publication at: <https://www.researchgate.net/publication/365686988>

# Autochthonous *Angiostrongylus cantonensis* Lungworms in Urban Rats, Valencia, Spain, 2021

Article in *Emerging Infectious Diseases* · December 2022

DOI: 10.3201/eid2812.220418

CITATIONS

0

READS

100

6 authors, including:



**Maria Teresa Galan-Puchades**  
University of Valencia

137 PUBLICATIONS 891 CITATIONS

[SEE PROFILE](#)



**Antonio Osuna**  
University of Granada

283 PUBLICATIONS 4,088 CITATIONS

[SEE PROFILE](#)



**Sandra Sáez-Durán**  
University of Valencia

35 PUBLICATIONS 367 CITATIONS

[SEE PROFILE](#)



**Rubén Bueno Marí**  
Laboratorios Lokímica

255 PUBLICATIONS 1,196 CITATIONS

[SEE PROFILE](#)

Some of the authors of this publication are also working on these related projects:



Mosquitoes and pathogens associated in the Barcelona Zoo: feeding behaviour of vectors, implications on disease transmission and proposals for an integrated pest management [View project](#)



Nescotiger: New strategies for the control of the tiger mosquito in residential areas [View project](#)

several genetic and antigenic differences and suggested poor reactivity to the contemporary human seasonal influenza vaccine.

This reported case is considered independent of the previously reported variant infection in Denmark (4), because the 2 viruses are genetically distinct (Table). The symptoms were also different; the earlier case was in an elderly patient with comorbidities who experienced classical influenza-like illness, but in this case, a previously healthy adult of younger age experienced unusual severe and sudden illness. Influenza-associated convulsions in adults are rare (6) and mostly accompanied by fever or encephalitis, which was not observed in this patient.

The identification of variant IAVs emphasizes the zoonotic potential of these strains and highlights the importance of continued monitoring of both human and swine IAVs. The reported case suggests a need for focusing on early registration of swine exposure for humans with influenza-like illness, as well as increased measures to reduce the swine IAV exposure risk for people with occupational contact with swine.

### Acknowledgments

We thank the laboratory technicians from the National Influenza Center at Statens Serum Institute for technical assistance in the laboratory. We also thank the patient for collaboration through the interviews and for allowing publication of the case.

This work has been conducted as part of the national influenza surveillance in Denmark, which is funded by the government, and as part of the FluZooMark project, funded by the Novo Nordisk Foundation (grant no. NNF19OC0056326).

### About the Author

Ms. Andersen is a PhD student at the Department of Health Technology, Technical University of Denmark and at the National Influenza Center, Statens Serum Institut, Denmark. Her research interests are the genetic evolution of influenza A viruses at the human/swine interface and using bioinformatics to identify genetic markers of zoonotic transmission.

### References

1. Freidl GS, Meijer A, de Bruin E, de Nardi M, Munoz O, Capua I, et al.; FLURISK Consortium. Influenza at the animal-human interface: a review of the literature for virological evidence of human infection with swine or avian influenza viruses other than A(H5N1). *Euro Surveill.* 2014;19:20793. <https://doi.org/10.2807/1560-7917.ES2014.19.18.20793>

2. Parys A, Vandoorn E, King J, Graaf A, Pohlmann A, Beer M, et al. Human infection with Eurasian avian-like swine influenza A(H1N1) virus, the Netherlands, September 2019. *Emerg Infect Dis.* 2021;27:939-43. <https://doi.org/10.3201/eid2703.201863>
3. Dürrwald R, Wedde M, Biere B, Oh DY, Heßler-Klee M, Geidel C, et al. Zoonotic infection with swine A/H1<sub>av</sub>N1 influenza virus in a child, Germany, June 2020. *Euro Surveill.* 2020;25:2001638. <https://doi.org/10.2807/1560-7917.ES.2020.25.42.2001638>
4. Nissen JN, George SJ, Hjulsgager CK, Krog JS, Nielsen XC, Madsen TV, et al. Reassortant influenza A(H1N1)pdm09 virus in elderly woman, Denmark, January 2021. *Emerg Infect Dis.* 2021;27:3202-5. <https://doi.org/10.3201/eid2712.211361>
5. Ryt-Hansen P, Krog JS, Breum SØ, Hjulsgager CK, Pedersen AG, Trebbien R, et al. Co-circulation of multiple influenza A reassortants in swine harboring genes from seasonal human and swine influenza viruses. *eLife.* 2021;10:10. <https://doi.org/10.7554/eLife.60940>
6. Ruisanchez-Nieva A, Martinez-Arroyo A, Gomez-Beldarrain M, Bocos Portillo J, Garcia-Monco JC. Influenza-associated seizures in healthy adults: Report of 3 cases. *Epilepsy Behav Case Rep.* 2017;8:12-3. <https://doi.org/10.1016/j.ebcr.2017.01.003>

Address for correspondence: Klara Marie Andersen, Statens Serum Institut, Artillerivej 5, 2300 Copenhagen S, Denmark; email: kman@ssi.dk

## Autochthonous *Angiostrongylus cantonensis* Lungworms in Urban Rats, Valencia, Spain, 2021

María Teresa Galán-Puchades,<sup>1</sup> Mercedes Gómez-Samblás,<sup>1</sup> Antonio Osuna, Sandra Sáez-Durán, Rubén Bueno-Marí, Màrius V. Fuentes

Author affiliations: University of Valencia, Burjassot-Valencia, Spain (M.T. Galán-Puchades, S. Sáez-Durán, R. Bueno-Marí, M.V. Fuentes); University of Granada, Granada, Spain (M. Gómez-Samblás, A. Osuna); Laboratorios Lokímica, Catarroja-Valencia, Spain (R. Bueno-Marí)

DOI: <https://doi.org/10.3201/eid2812.220418>

<sup>1</sup>These first authors contributed equally to this article.

To determine the role of rats as potential reservoirs of zoonotic parasites, we examined rats trapped in urban sewers of Valencia, Spain, in 2021. Morphologic and molecular identification and sequencing identified autochthonous *Angiostrongylus cantonensis* nematodes, the most common cause of human eosinophilic meningitis, in pulmonary arteries of *Rattus norvegicus* and *R. rattus* rats.

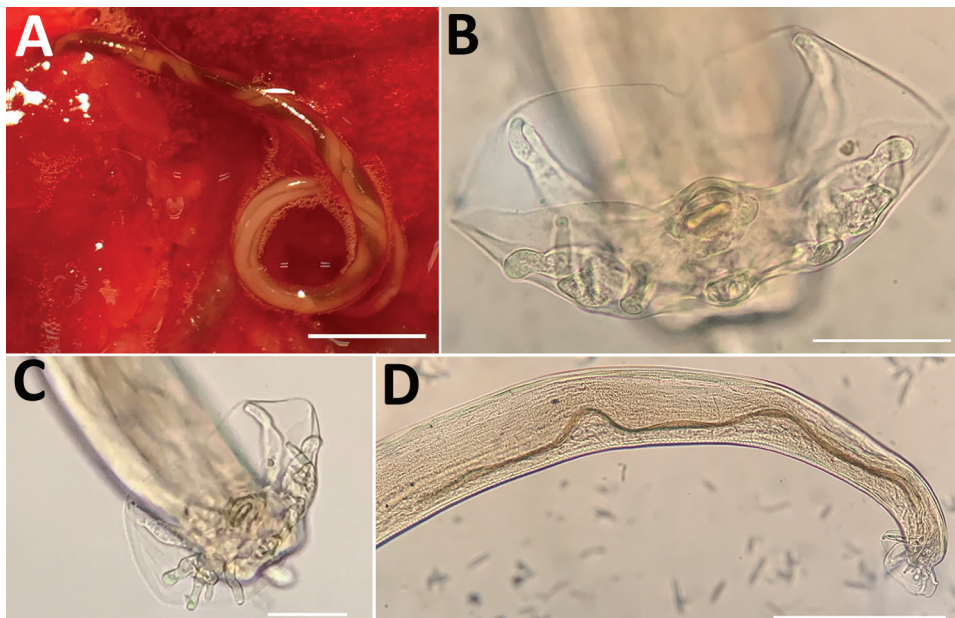
In Valencia, Spain, permanent rodent control campaigns are the responsibility of The Pest Control Section of the Health Service of Valencia City Council. As part of its tasks, the Section traps *Rattus norvegicus* and *R. rattus* rats in standard snap traps in the sewage system of Valencia. The trapped rodents were preserved in their entirety at  $-20^{\circ}\text{C}$  and subsequently, to determine the potential reservoir role of zoonotic parasitic diseases, we defrosted the rats and analyzed the endoparasites.

In 2021, we collected 29 adult *A. cantonensis* nematodes (21 female and 8 male) from the organs of the first 27 trapped rats (25 *R. norvegicus* and 2 *R. rattus*) under a stereomicroscope once the rats had been dissected. The nematodes were detected in the pulmonary arteries of 2 *R. norvegicus* rats and 1 *R. rattus* rat; 7 young nematode adults were also found in the brain of the same *R. rattus* rat. Adult females showed the typical barber pole spiral of lungworms of the genus *Angiostrongylus* (Figure, panel A). After clarifying adult male worms with Amman's lactophenol and studying their morphology (Figure, panels B-D), we found that the measurements were consistent with rat lungworm species of *A. cantonensis* (Table) (1,2).

The parasite morphology, its microhabitat, and the nature of the definitive hosts clearly suggested

that the parasites were *A. cantonensis*. To confirm species identification, we isolated total genomic DNA by using the DNeasy Blood and Tissue kit (QIAGEN, <https://www.qiagen.com>) according to the manufacturer's instructions. We confirmed nematode species identity by PCR and sequencing of the cytochrome c oxidase subunit 1 (3); all sequences obtained were clustered with *A. cantonensis*. The phylogenetic tree grouped the *A. cantonensis* lungworms from Valencia close to the published sequences MK570629 and MN227185, corresponding to *A. cantonensis* lungworms isolated from Tenerife and Mallorca, respectively (Appendix Figure 1, <https://wwwnc.cdc.gov/EID/article/28/12/22-0418-App1.pdf>). We submitted the sequences we obtained to GenBank (accession no. ON819883 for the female specimen and ON819884 for the male). Likewise, when we sequenced the second internal transcribed spacer region, we found that our specimens formed a clade that differed from the other species of *Angiostrongylus* (Appendix Figure 2). We also submitted those sequences to GenBank (accession no. OM829831 for the male specimen and OM829832 for the female).

Male and female adult *A. cantonensis* lungworms live in the pulmonary arteries of *Rattus* rats, their preferred definitive hosts (4). Intermediate hosts are terrestrial or freshwater mollusks, such as snails and slugs. The female worms lay eggs, which give rise to L1 larvae that penetrate the alveolae and are swallowed by the rat and shed in the feces. After ingestion by an intermediate host, L1 larvae molt into L3 larvae. When infected mollusks are ingested by a rat, the subsequent phase takes place in the rat brain, where L3 larvae turn into young



**Figure.** *Angiostrongylus cantonensis* lungworms from lungs of rats trapped in Valencia, Spain, 2021. A) Adult female with characteristic barber-pole appearance. Scale bar indicates 500  $\mu\text{m}$ . B, C) Copulatory bursae of 2 male worms supported by bursal rays. Scale bars indicate 50  $\mu\text{m}$ . D) Detail of the long spicula of a male worm. Scale bar indicates 300  $\mu\text{m}$ .

**Table.** Measurements of 4 *Angiostrongylus cantonensis* male lungworms collected from rats trapped in Valencia, Spain, 2021\*

Morphologic character	Range, mm	Mean, mm
Total length	14.08–21.08	17.21
Maximum width	0.25–0.38	0.28
Esophagus length	0.29–0.36	0.32
Esophagus maximum width	0.07–0.09	0.08
Distance from excretory pore to cephalic extremity	0.38–0.47	0.41
Spicules length	1.14–1.27	1.21
Gubernaculum length	0.10–0.13	0.11

\*one from *Rattus norvegicus* and 3 from *R. rattus* rats.

adults (L5). After leaving the central nervous system, L5 young adult worms reach the pulmonary arteries, where they mature and reproduce. Paratenic hosts include crabs, shrimp, frogs, and lizards (4).

Angiostrongyliasis is a foodborne disease; therefore, human infection requires ingestion of raw/poorly cooked intermediate or paratenic hosts. Another source of infection is lettuce contaminated with infective larvae released by an intermediate host (5). Hence, when humans accidentally ingest L3 larvae, the larvae penetrate the intestinal wall and travel through the bloodstream to the brain, where they can cause acute eosinophilic meningitis (neuroangiostrongyliasis). Severe cases can result in radiculitis, cranial neuropathy, myelitis, encephalopathy, coma, and even death. Usually, the nematodes die in the central nervous system (6).

Neuroangiostrongyliasis is a global emerging disease with serious implications for animal and public health (4). Globalization has helped disperse, and probably continues to disperse, rat lungworms. Infected rats (and snails) travel by ship, thereby transferring the parasite between continents and countries (7). Infected rats have been found near the port of Valencia but also several kilometers from the coast, suggesting a wide distribution of the rat lungworm in the city (Appendix Figure 3).

*A. cantonensis* lungworms have been reported widely in Asia, Africa, and America. However, in Europe, they have thus far been reported exclusively at the insular level, specifically in *R. norvegicus* and *R. rattus* rats in Tenerife (Canary Islands) and in *Atelerix algirus* hedgehogs in Mallorca (Balearic Islands) (2,8,9). Although a possible autochthonous human case of *A. cantonensis* infection was (immunologically) diagnosed in France, the possibility of its being an imported case was not ruled out (10).

*A. cantonensis* lungworms, a dangerous invasive species, agents of a potentially fatal emerging infectious disease, are spreading into locations beyond their typical tropical/subtropical distribution, probably favored not only by globalization but also by climate change. Epidemiologic surveys of rat populations in Europe, preferably in urban/

peri-urban areas, with the involvement of government entities, pest control agencies, and experts in parasitic zoonoses, should help minimize future potential human infections.

### Acknowledgment

We thank the Health Service of Valencia City Council for overseeing and promoting this research in the city.

### About the Author

Prof. Galán-Puchades is director of the Research Group on Parasites and Health of the University of Valencia. Her research interests include neglected parasitic diseases.

### References

1. Yousif F, Ibrahim A. The first record of *Angiostrongylus cantonensis* from Egypt. *Z Parasitenkd.* 1978;56:73–80. <https://doi.org/10.1007/BF00925940>
2. Foronda P, López-González M, Miquel J, Torres J, Segovia M, Abreu-Acosta N, et al. Finding of *Parastrongylus cantonensis* (Chen, 1935) in *Rattus rattus* in Tenerife, Canary Islands (Spain). *Acta Trop.* 2010;114:123–7. <https://doi.org/10.1016/j.actatropica.2010.02.004>
3. Rodpai R, Intapan PM, Thanchomnang T, Sanpool O, Sadaow L, Laymanivong S, et al. *Angiostrongylus cantonensis* and *A. malaysiensis* broadly overlap in Thailand, Lao PDR, Cambodia and Myanmar: a molecular survey of larvae in land snails. *PLoS One.* 2016;11:e0161128. <https://doi.org/10.1371/journal.pone.0161128>
4. Barratt J, Chan D, Sandaradura I, Malik R, Spielman D, Lee R, et al. *Angiostrongylus cantonensis*: a review of its distribution, molecular biology and clinical significance as a human pathogen. *Parasitology.* 2016;143:1087–118. <https://doi.org/10.1017/S0031182016000652>
5. Waugh CA, Shafir S, Wise M, Robinson RD, Eberhard ML, Lindo JF. Human *Angiostrongylus cantonensis*, Jamaica. *Emerg Infect Dis.* 2005;11:1977–8. <https://doi.org/10.3201/eid1112.050217>
6. Johnston DI, Dixon MC, Elm JL, Calimlim PS, Sciullini RH, Park SY. Review of cases of angiostrongyliasis in Hawaii, 2007–2017. *Am J Trop Med Hyg.* 2019;101:608–16. <https://doi.org/10.4269/ajtmh.19-0280>
7. Hochberg NS, Blackburn BG, Park SY, Sejvar JJ, Effler PV, Herwaldt BL. Eosinophilic meningitis attributable to *Angiostrongylus cantonensis* infection in Hawaii: clinical characteristics and potential exposures. *Am J Trop Med Hyg.* 2011;85:685–90. <https://doi.org/10.4269/ajtmh.2011.11-0322>
8. Martín-Carrillo N, Feliu C, Abreu-Acosta N, Izquierdo-Rodríguez E, Dorta-Guerra R, Miquel J, et al. A peculiar distribution of the emerging nematode

*Angiostrongylus cantonensis* in the Canary Islands (Spain): recent introduction or isolation effect? *Animals (Basel)*. 2021;11:1267. <https://doi.org/10.3390/ani11051267>

9. Paredes-Esquivel C, Sola J, Delgado-Serra S, Puig Riera M, Negre N, Miranda MA, et al. *Angiostrongylus cantonensis* in North African hedgehogs as vertebrate hosts, Mallorca, Spain, October 2018. *Euro Surveill*. 2019;24:1900489. <https://doi.org/10.2807/1560-7917.ES.2019.24.33.1900489>
10. Nguyen Y, Rossi B, Argy N, Baker C, Nickel B, Marti H, et al. Autochthonous case of eosinophilic meningitis caused by *Angiostrongylus cantonensis*, France, 2016. *Emerg Infect Dis*. 2017;23:1045–6. <https://doi.org/10.3201/eid2306.161999>

Address for correspondence: María Teresa Galán-Puchades, Department of Pharmacy, Pharmaceutical Technology and Parasitology, Faculty of Pharmacy, University of Valencia Av. Vicent Andrés Estellés s/n, 46100 Burjassot-Valencia, Spain; email: mteresa.galan@uv.es

## Laboratory Features of Trichinellosis and Eosinophilia Threshold for Testing, Nunavik, Quebec, Canada, 2009–2019

Luke B. Harrison, Michael D. Libman, Chelsea Caya, Momar Ndao, Cedric P. Yansouni

Author affiliations: McGill University Health Centre, Montreal, Quebec, Canada (L.B. Harrison, M.D. Libman, C. Caya, C.P. Yansouni); National Reference Centre for Parasitology, Montreal (M. Ndao)

DOI: <https://doi.org/10.3201/eid2812.221144>

Prolonged eosinophilia is characteristic of trichinellosis. To determine the optimal eosinophil threshold for reflex *Trichinella* testing, we examined all 43 cases in Nunavik, Quebec, Canada, during 2009–2019. Using receiver operating characteristic analysis, we determined that eosinophil counts  $\geq 0.8 \times 10^9$  cells/L should prompt consideration of trichinellosis and testing to rapidly identify potential outbreaks.

*Trichinella nativa* infection is associated with ingestion of parasitized sylvatic animals and periodic outbreaks among residents of northern Canada (1–3).

In the Arctic region of Nunavik in Quebec, outbreaks associated with polar bear and walrus consumption have prompted public health interventions, including a highly successful community-led active surveillance system that examines hunted meat for evidence of *Trichinella* encystment (4,5). We report a 10-year case series of *Trichinella* infection in Nunavik and describe the laboratory features. Eosinophilia is a well-characterized feature of infection that is readily available for most cases. We performed receiver operating characteristic (ROC) analysis to define an optimal threshold of eosinophilia to prompt reflex *Trichinella* antibody testing and rapid reporting to public health authorities for timely outbreak investigation (1–3).

In a retrospective test-negative case-control study, we reviewed laboratory and public health records to identify cases of trichinellosis in Nunavik that occurred from 2009 through 2019. Our study was approved by the Research Institute of the McGill University Health Centre Research and Ethics Board (REB #2020-5312).

We first reviewed all requests for *Trichinella* serologic testing sent from Quebec to the National Reference Centre for Parasitology, the only testing site for Quebec, during 2009–2019 (Appendix, <https://wwwnc.cdc.gov/EID/article/28/12/22-1144-App1.pdf>). To define an initial set of cases (with positive *Trichinella* serologic results), we selected specimens originating from Nunavik. One author (L.B.H.) reviewed the charts and confirmed cases if the clinical evolution was compatible with the positive serologic results. Because trichinellosis is notifiable by provincial law, we cross-referenced cases with the public health database to identify other cases determined epidemiologically and reviewed those charts. We defined a set of region-matched controls as those with negative *Trichinella* serologic results. Those controls are therefore persons from the general population, from the same region who had clinical manifestations that prompted testing for trichinellosis. Although serologic results early in the disease course could be negative, chart review of controls did not yield additional suspected cases on the basis of clinical evolution. We extracted available clinical and laboratory data by chart review at the McGill University Health Centre and at regional health centers in Nunavik. We calculated summary statistics and tests (*t*-test and  $\chi^2$ ), comparing cases and controls by using R (6), and generated ROC curves by using the pROC R package (7).

We identified 43 cases of trichinellosis and a set of 31 region-matched controls (Table). We excluded 4 possible case-patients with weakly positive serologic results but ambiguous clinical manifestations consistent with past infection. Information on signs and